CASE REPORT

An Unusual Case Of Abdominal Wall Hematoma After Renal Allograft Biopsy

Geeta*, Rakesh Gupta, Tushar Gupta*, Pankaj Beniwal***, Vinay Malhotra****, Dhananjai Agarwal****, SitaRam*, Niranjan Gogoi***

ABSTRACT

Renal biopsy is often required to diagnose allograft dysfunction. Although it's a safe procedure, complications do occur. We report an unusual case of anterior abdominal wall hematoma after renal allograft biopsy. The patient developed progressive swelling over allograft site. Initially patient was managed conservatively followed by percutaneous drain. Color doppler evaluation of overlying abdominal wall can help to look for significant vessels before biopsy procedure and avoid such complications.

Key Words: Renal biopsy, Allograft, Hematoma.

INTRODUCTION

Renal allograft biopsies are done for evaluation of allograft dysfunction after ruling out pre-renal and post renal causes. The use of ultrasound guidance has reduced the chances of significant bleeding. This is a case report of enlarging abdominal wall hematoma after percutaneous renal allograft biopsy which was managed with an abdominal wall drain.

CASE REPORT

A 46 year old female who underwent renal transplantation 12 years ago presented to our hospital with asymptomatic increase in serum creatinine. Systemic examination was unremarkable. Tacrolimus levels were normal. Renal biopsy was done, after ruling out pre-renal and post renal causes, for evaluation of graft dysfunction.

Renal allograft biopsy was done under USG guidance from the upper pole using an 18 G needle after checking the coagulation parameters. A tender swelling developed at the biopsy site 4-6 hours after the procedure which was gradually increasing in size. There was no associated hematuria. USG showed organised collection of 139x70 mm around tranplanted kidney, likely hematoma. Doppler study didn't show any evidence of pseudoaneurysm or arteriovenous fistula. Patient's hematocrit dropped and hence blood transfusions were given. The hematoma further increased in size the next day and CT abdomen was done which was suggestive of large hypodense collection in lateral abdominal wall (fig 1,2). CT angiography was done to look for the site of bleed. The bleeding vessel could not be identified.

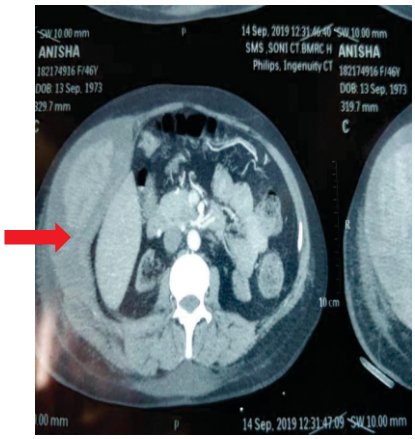

Fig 1

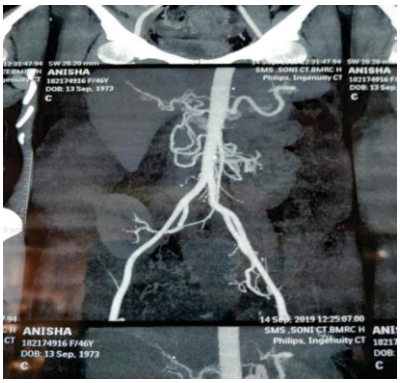

Fig 2

*Resident, **Associate Professor, ***Professor, ****Senior Professor
Department of Nephrology, SMS Medical College & Hospital, Jaipur
Corresponding Author:
Dr. Shubham Agarwal
Resident Doctor
Department of Medicine, Mahatma Gandhi Medical College
Jaipur.
Email:drdhananjainephro@yahoo.com
Ph. No. 9414459790

The patient was managed conservatively with bed rest and regular monitoring of hematocrit. Hematoma stopped expanding 3 days later but due to persistent tenderness abdominal wall drain was inserted for early drainage of hematoma. Patient responded well to this management and was kept on regular follow up.

DISCUSSION

Renal biopsy is usually recognized as a safe procedure in native and transplant kidney.[1,2] Biopsy procedures of renal allograft are known to have a higher incidence of gross hematuria, hematoma formation, hemoperitoneum and AV fistulae.[3,4] While minor complications usually resolve spontaneously, major complications require further treatment, sometimes even evacuation of hematoma or nephrectomy.[5]

Injury to arteries in abdominal wall can occur during paracentesis,chest tube insertion and rarely following percutaneous biopsy.[6,7,8] The arteries most commonly injured are the branches of superior epigastric artery, inferior epigastric artery or circumflex iliac artery.[7,8,9] In this case we were suspecting an injury to anterior abdominal wall vessel which was responsible for the formation of hematoma although the exact site of bleed could not be identified. Knowledge of vasculature of anterior abdominal wall is useful in such circumstances and Doppler study can help to identify the source of bleed.

CONCLUSION

Abdominal wall hematoma is a rare complication of allograft biopsy. Although there have been quite a few case reports of renal and perirenal hematoma after allograft biopsy, anterior abdominal wall hematoma has been reported scarcely. The person performing biopsy should be aware that injury to abdominal wall vessels can occur during the procedure and these should be evaluated as the cause of bleed if no renal parenchymal lesion is obvious. A color Doppler evaluation of the abdominal wall overlying the allograft can be useful to diagnose such cases.

REFERENCES

1. Tondel C, Vikse BE, Bostad L, Svarstad E. Safety and complications of percutaneous kidney biopsies 1988-2010. Clin J Am SocNephrol. 2012;7:1591-1597.
2. Esposito V, Mazzon G, Baiardi P, et al. Safety and adequacy of percutaneous kidney biopsy performed by nephrology trainees. BMC Nephrology. 2018;19:14.
3. Parrish AE. Complicationc of percutaneous biopsy: a review of 37 years' experience. ClinNephrol. 1992;38:135-41.
4. Gainza FJ, Minguela I, Lopez-Vidaur I, Ruiz LM, Lampreabe I. Evaluation of complications due to percutaneous renal biopsy in allografts and native kidneys with color-coded doppler sonography. ClinNephrol. 1995;43:303-8.
5. Burstein DM, Korbet SM, Schwartz MM. The use of the automatic core biopsy system in percutaneous renal biopsies: a comparative study. Am J Kidney Dis. 1993;22:545-52.
6. Sadat U, Jah A, Ward N, Gaunt M. Superior epigastric artery pseudoaneurysm-A rare complication of chest drain insertion in coronary artery bypass grafting. J CardiothoracSurg2007;2:21.
7. Lam EY, McLafferty RB, Taylor LM Jr., Moneta GL, Edwards JM, Barton RE et al.Inferior epigastric artery pseudoaneurysm: A complication of paracentesis. J VascSurg1998;28:566-9.
8. Todd AW. Inadverent puncture of inferior epigastric artery during needle biopsy with fatal outcome. ClinRadiol2001;56:989-90.
9. Satija B, Kumar S, Duggal RK, Kohli S. Deep circumflex iliac artery pseudoaneurysm as a complication of paracentesis. J Clin Imaging Sci2012;2:10.